



# A new methodology for the measurement of the root canal curvature and its 3D modification after instrumentation

Asterios Christodoulou, Georgios Mikrogeorgis, Triantafillia Vouzara, Konstantinos Papachristou, Christos Angelopoulos, Nikolaos Nikolaidis, Ioannis Pitas & Kleoniki Lyroutdia

To cite this article: Asterios Christodoulou, Georgios Mikrogeorgis, Triantafillia Vouzara, Konstantinos Papachristou, Christos Angelopoulos, Nikolaos Nikolaidis, Ioannis Pitas & Kleoniki Lyroutdia (2018) A new methodology for the measurement of the root canal curvature and its 3D modification after instrumentation, Acta Odontologica Scandinavica, 76:7, 488-492, DOI: [10.1080/00016357.2018.1440321](https://doi.org/10.1080/00016357.2018.1440321)

To link to this article: <https://doi.org/10.1080/00016357.2018.1440321>



Published online: 15 Feb 2018.



Submit your article to this journal [↗](#)

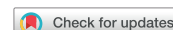

Article views: 164



View Crossmark data [↗](#)

ORIGINAL ARTICLE



## A new methodology for the measurement of the root canal curvature and its 3D modification after instrumentation

Asterios Christodoulou<sup>a</sup>, Georgios Mikrogeorgis<sup>a</sup> , Triantafillia Vouzara<sup>a</sup>, Konstantinos Papachristou<sup>b</sup>, Christos Angelopoulos<sup>c</sup>, Nikolaos Nikolaidis<sup>b</sup>, Ioannis Pitas<sup>b</sup> and Kleoniki Lyroutdia<sup>a</sup>

<sup>a</sup>Department of Endodontology, School of Dentistry, Aristotle University of Thessaloniki, Thessaloniki, Greece; <sup>b</sup>Artificial Intelligence and Information Analysis Laboratory, Department of Informatics, Aristotle University of Thessaloniki, Thessaloniki, Greece; <sup>c</sup>Department of Oral Surgery, Implantology and Dental Radiology, School of Dentistry, Aristotle University of Thessaloniki, Thessaloniki, Greece

### ABSTRACT

**Objective:** In this study, the three-dimensional (3D) modification of root canal curvature was measured, after the application of Reciproc instrumentation technique, by using cone beam computed tomography (CBCT) imaging and a special algorithm developed for the 3D measurement of the curvature of the root canal.

**Materials and methods:** Thirty extracted upper molars were selected. Digital radiographs for each tooth were taken. Root curvature was measured by using Schneider method and they were divided into three groups, each one consisting of 10 roots, according to their curvature: Group 1 (0°–20°), Group 2 (21°–40°), Group 3 (41°–60°). CBCT imaging was applied to each tooth before and after its instrumentation, and the data were examined by using a specially developed CBCT image analysis algorithm.

**Results:** The instrumentation with Reciproc led to a decrease of the curvature by 30.23% (on average) in all groups.

**Conclusions:** The proposed methodology proved to be able to measure the curvature of the root canal and its 3D modification after the instrumentation.

### ARTICLE HISTORY

Received 28 October 2017

Revised 3 January 2018

Accepted 6 February 2018

### KEYWORDS

CBCT; instrumentation; reciproc; root canal curvature

### Introduction

One of the main goals of root canal treatment is cleaning and shaping the root canal system while maintaining its original configuration. Over the years, many nickel–titanium (Ni–Ti) mechanical instruments have been developed and proposed to improve root canal preparation.

Recently, several single-file systems for root canal instrumentation have been introduced to the market. One of them is the Reciproc system (VDW GmbH, Munich, Germany). Reciproc files are available in three sizes: R25-taper 08; R40-taper 06; R50-taper 05. Single use, reciprocating motion and M-wire alloy are the basic characteristics of this system. The M-wire alloy increases flexibility and improves its resistance to cyclic fatigue [1–4]. Furthermore, the reciprocating motion has been shown to maintain root canal curvature [1–5].

Many studies have been published, which tested the abilities and effectiveness of the specific system. However, there are many different procedural errors that may occur during the instrumentation of a root canal. A very common one is the modification of the root canal curvature. Despite the importance of canal curvature in endodontic instrumentation, only a few studies have tried to measure it. Schneider was the first which tried to measure the root canal curvature as the acute angle between the long axis of the canal and a

straight line from the apical foramen to the point of the initial curvature on radiographs [6]. Then, Weine [7] attempted to measure the curvature using the acute angle between lines passing through the apical and coronal portions. In other studies the curvature was measured radiographically by placing files in the root canals of extracted molars [8,9]. In 2005, Gunday et al. [10] compared some of these radiographic methods for measuring curvature, when placing #10 K-files in the mesiobuccal canals of 100 mandibular first and second molars. A first attempt to develop a mathematical model of the root canal axis using radiographic data was made by Nagy et al. [11,12]. Furthermore, Schafer et al. [13] proposed that a radius of curvature must be determined mathematically from the radiographs to better describe root canal curvature. In contrast to these two-dimensional radiographic analyses, the three-dimensional (3D) measurement of canal curvature by micro-computed tomography (microCT) was first reported by Peters et al. [14] in 2000. Then, Bergmans et al. [15] quantitatively evaluated the root canal transportation and centering ability in a mandibular molar using microCT and a 3D mathematical model. Later, Lee et al. [16] accurately measured the 3D curvature in maxillary first molar root canals using microCT and mathematical modelling software.

The aim of this study was to evaluate the suitability of a new methodology, that uses cone beam computed tomography (CBCT) imaging and a root canal curvature estimation algorithm developed in the AIIA (Artificial Intelligence and Information Analysis) Laboratory, Department of Informatics, Aristotle University of Thessaloniki, Greece, for the accurate measurement of the root canal curvature and its 3D modification after the instrumentation.

## Materials and methods

Thirty first and second upper molars, extracted for periodontal or orthodontic reasons, were selected. They were debrided with ultrasonic scalers and washed several times in water. Then, they were stored in 2.5% NaOCl for 24 h, in order to be sufficiently disinfected. After that, they were stored in distilled water at 4 °C until further processing. The teeth were embedded in the radiolucent Express vinyl polysiloxane impression putty material (3M ESPE, St. Paul, MN, USA), so as to be kept in a steady position with respect to the horizontal plane during processing. Digital radiographs were taken for each tooth at buccopalatal and mesiodistal direction, by using the RadioVisioGraphy (RVG) direct digital intraoral radiography system (Trophy Radiology S.A., Paris, France) and an Oralix AC Densomat X-ray machine (Gendex Dental System, Milano, Italy, 65 kV peak and 7.5 mA mean) with an exposure time of 0.08 s. The X-ray tube, the sensor and the position of the embedded tooth were fixed in such a way that the central X-ray beam was perpendicular to the tooth axis and the sensor. The distance between the tube and the tooth and between the tooth and the sensor was also fixed. The curvature of each root was measured on the radiographic images according to the Schneider method [6,17]. Three groups, each one consisting of 10 palatal, distobuccal or mesiobuccal roots were made, according to their curvature: Group 1 (0°–20°), Group 2 (21°–40°) and Group 3 (41°–60°). CBCT imaging was applied to each tooth, by using the NewTom VGi 7FOV CBCT device (NewTom, Verona, Italy, 110 KB, exposure time: 5.4 s, voxel size: 0.125 mm).

Access cavities were prepared by using drills placed on a high-speed and a low-speed handpieces. Apical patency was confirmed by introducing a #10 K-file (Maillefer-Dentsply, Ballaigues, Switzerland), until it was visible through the apical foramen. Working length was established by subtracting 0.5 mm from that point. The root canals were instrumented by using the R25 instrument of Reciproc system according to manufacturer's instructions. A 27-gauge endodontic needle and 2 ml of 2.5% NaOCl solution were used for irrigation after each instrumentation. All canals were prepared by the same experienced operator.

Next, a second CBCT imaging followed for each tooth, under the same conditions as the first one. CBCT data from each tooth were examined by using the above mentioned root canal curvature estimation algorithm that was developed for this study. The calculation of the curvature of the root canal consisted of two steps: (a) the automatic determination of the root canal central axis and (b) the calculation of the axis curvature.


- In this algorithm, a tooth was automatically represented in volumetric form, where the volume was formed by the CBCT tooth slices. Each slice had an axial thickness of 0.125 mm. The outline of the automatic procedure used to find the roots was the following one: First, the pixels of the slice that belong to the background were distinguished from the ones that belong to the root canal [18]. Then, the pixels that form the root canal were found. For each slice, the corresponding root canal center defined the central axis point of the root canal for this slice (Figure 1). This process was repeated for all the slices that form the CBCT volume, resulting in a series of points on the root canal axis.
- To calculate the curvature of the central axis, the method presented by Lee et al. [16] in 2006, was used. Specifically, a cubic B-spline curve of 4th degree to interpolate the points of the root canal axis was used. Then, the formula for the curvature calculation on continuous curves was used, in order to calculate the curvature of each axis point and measure the overall average curvature of the root canal [15,16].

This root canal curvature estimation algorithm can be used in any tooth volumes' image, whether it comes from CBCT (as is the case here) or from microCT.

## Results

With this methodology the imaginary central axis of each root canal was automatically visualized graphically. At each point along the root canal axis, the radius of curvature of the tangential circle was measured. The radius of curvature was inverted and graphed to provide a measure of canal curvature at each point along the axis. Thus, the root canal curvature in the present study was measured in  $\text{mm}^{-1}$ . So, a bigger curvature value shows a more curved root canal.

The main goal of this study was not to evaluate the shaping ability of Reciproc reciprocating single file system. It must



**Figure 1.** CBCT slice at the cervical third of tooth #2 (Group 3) after the processing with the developed algorithm. The palatal root canal is segmented (white) and the corresponding root canal center is defined (black).

be mentioned that decrease of the curvature in all root canals instrumented with Reciproc was calculated using this methodology. The preparation led to a decrease of the root canal curvature by 30.23% (on average) in all groups. More specifically, the percentage of the root canal curvature decrease in each group was: Group 1 (27.59%), Group 2 (28.83%) and Group 3 (34.28%) (Table 1). Furthermore, the developed algorithm gave the ability to visualize each root canal and its central axis, before and after the instrumentation with Reciproc. By using this algorithm, the root canal was represented as white, while its central axis was represented as black line (Figure 2).

During the preparation of the curved root canals, no instrument was fractured and no overextension of preparation was noticed.

### Discussion

The main goal of this study was to evaluate the ability of this specifically developed algorithm to calculate the curvature of the root canal and its 3D modification after the instrumentation. The basic advantage of the employed root canal curvature estimation algorithm is that it uses the 3D form of the root canal, as visualized in CBCT images, while Schneider technique is a 2D one and calculates the curvature of the root canal using radiographic images [6,17]. Weine [7] attempted to measure the curvature using the acute angle between lines passing through the apical and coronal portions. In other studies the curvature measured radiographically by placing files in the root canals of extracted molars [8,9]. They found curvature in all of the canals and the presence of secondary curvature in a direction opposite to that

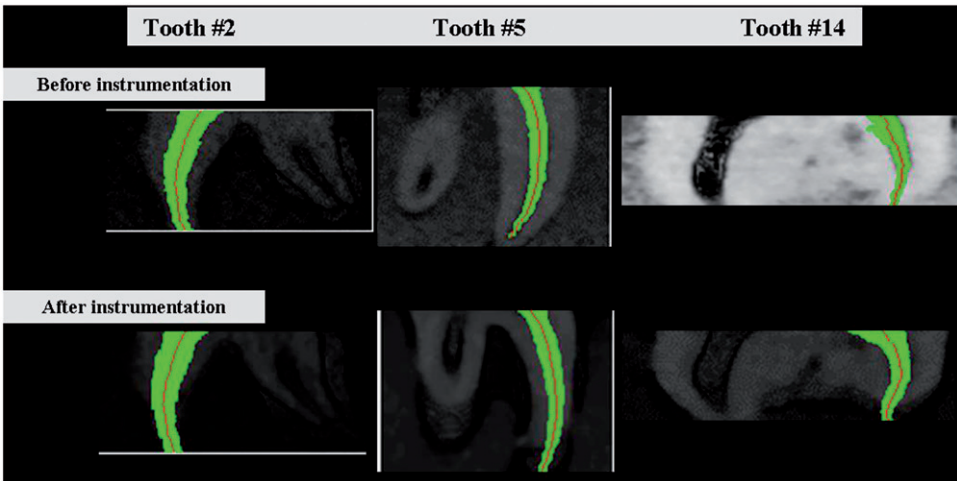
of the principle curve. This confirmed the complex 3D characteristics of canal curvature and the frequency of secondary curves. In 2005, Gunday et al. [10] compared some of these radiographic methods for measuring curvature when placing #10 K-files in the mesiobuccal canals of 100 mandibular first and second molars. They found that there were statistically significant differences between the techniques because the Schneider angle overemphasized coronal curvature and the Weine technique accommodated the apical segment. In the proposed methodology, the radius of the tangential circle was measured at each point along the imaginary 3D central axis of the root canal. To this end, the developed algorithm uses every point of the root canal central axis and calculates the curvature in 3D.

The 3D measurement of canal curvature by microCT was first reported by Peters et al. [14] in 2000. Then, Bergmans et al. [15] quantitatively evaluated the root canal transportation and centering ability in a mandibular molar using microCT and a 3D mathematical model and later Lee et al. [16] accurately measured the 3D curvature in maxillary first molar root canals using microCT and mathematical modelling software. The aim of this study was to evaluate the suitability of a new methodology that uses CBCT imaging and a specifically developed algorithm, for the accurate measurement of the root canal curvature and its 3D modification after the instrumentation. As the root canal is a 3D structure, its curvature is best estimated using a 3D volumetric method [18]. As the root canal is very well visualized in a CBCT volume, there is no need to use 3D imaging techniques (e.g. microCT) that are not frequently used in clinical practice. Thus, any CBCT inaccuracies cannot influence the outcome of the root canal curvature measurement.

Both microCT and CBCT can noninvasively document the internal and external morphologies of a tooth, although their features are different [19–24]. MicroCT can facilitate detailed evaluation of the root canal morphology through simultaneous or separate 3D reconstruction of images, while it can also facilitate qualitative and quantitative assessments of the root canal anatomy [19–23]. However, it has disadvantages,

**Table 1.** The average curvature ( $\text{mm}^{-1}$ ) before and after the instrumentation with Reciproc and the percentage of curvature decrease in each group.

	Group 1	Group 2	Group 3
Before instrumentation	0.2569	0.2764	0.2634
After instrumentation	0.1860	0.1967	0.1731
Curvature decrease %	27.59	28.83	34.28



**Figure 2.** The palatal root canal from tooth #2 (Group 3), the mesiobuccal root canal from tooth #5 (Group 3) and the distobuccal root canal from tooth #14 (Group 1), as represented by the developed algorithm, before and after the instrumentation with Reciproc. The root canals are represented as white and their central axis as black line.



notably its cost, time required for scanning and reconstruction, the high radiation dose, and, more importantly, its unsuitability for clinical use [19–23]. Nevertheless, it is considered the reference (gold) standard for laboratory studies of root canal anatomy, as it provides a detailed and accurate information with regard to the root canal morphology [19–23]. On the other hand, CBCT is widely used for imaging the root canal morphology and is routinely used in clinical practice [19–24]. It has a reduced acquisition time and use lower irradiation doses. Its field of view is limited, but the spatial resolution is very good in all planes. It has been used to detect the root canal anatomy and canal variations in previous studies [19–24], proving to be a very useful technique for the assessment of root canal morphology. However, the evidence supporting its use as a standard method for the detection of root canal morphology is scarce [19–23]. The resolution of CBCT is lower than microCT. Continued advances in CBCT imaging (smaller voxel size/higher resolution) can help to better understand tooth anatomy before endodontic therapy and, thus, improve root canal treatment outcomes [19,20,23].

Reciproc reciprocating single file system were used in this study. Single use, reciprocating motion and M-wire alloy are the basic characteristics of this system. The M-wire alloy increases flexibility and improves its resistance to cyclic fatigue [1–4]. Moreover, the reciprocating motion has been shown to maintain root canal curvature [1–5]. Furthermore, Burklein et al. [2,3] reported that Reciproc maintained well the original curvature of severely curved canals in extracted teeth. Capar et al. [25] used CBCT imaging and found that WaveOne, Reciproc and OneShape maintained root canal curvature equally well and produced similar canal transportation during the preparation of mesial canals of mandibular molars. Likewise, Yoo and Cho [26] used simulated canals in resin blocks and found that WaveOne and Reciproc produced similar canal straightening and maintained the original canal curvature equally good. Therefore, Reciproc system selected for this study.

## Conclusions

The proposed methodology that uses CBCT imaging and a specifically developed algorithm proved to be able to measure the curvature of the root canal and its 3D modification after the instrumentation. However in order to come up with concrete conclusions regarding the merits of this methodology, a more thorough evaluation needs to be carried out; moreover the use of contemporary advanced CBCT machines (smaller voxel size/higher resolution) might help to have more precise and reliable results.

## Disclosure statement

All authors declare any financial support or relationships that may pose conflict of interest by disclosing any financial arrangements they have with a company whose product figures prominently in the submitted manuscript or with a company making a competing product, or any conflict relating to technology or methodology. Also all authors deny any conflicts of interest related to this study.

## ORCID

Georgios Mikrogeorgis  <http://orcid.org/0000-0003-0871-3243>

## References

- [1] Stern S, Patel S, Foschi F, et al. Changes in centering and shaping ability using three nickel titanium instrumentation techniques analysed by micro-computed tomography ( $\mu$ CT). *Int Endod J*. 2012;45:514–523.
- [2] Burklein S, Hinschitzka K, Dammaschke T, et al. Shaping ability and cleaning effectiveness of two single-file systems in severely curved root canals of extracted teeth: reciproc and WaveOne versus Mtwo and ProTaper. *Int Endod J*. 2012;45:449–461.
- [3] Burklein S, Benten S, Schafer E. Shaping ability of different single-file systems in severely curved root canals of extracted teeth. *Int Endod J*. 2013;46:590–597.
- [4] Marzouk AM, Ghoneim AG. Computed tomographic evaluation of canal shape instrumented by different kinematics rotary nickel-titanium systems. *J Endod*. 2013;39:906–909.
- [5] Plotino G, Ahmed HM, Grande NM, et al. Current assessment of reciprocation in endodontic preparation: a comprehensive review—Part II: properties and effectiveness. *J Endod*. 2015;41:1939–1950.
- [6] Schneider SW. A comparison of canal preparations in straight and curved root canals. *Oral Surg Oral Med Oral Pathol*. 1971;32:271–275.
- [7] Weine FS. *Endodontic therapy*. 3rd ed. St. Louis (MO, USA): Elsevier Mosby; 1982.
- [8] Cunningham CJ, Senia ES. A three-dimensional study of canal curvatures in the mesial roots of mandibular molars. *J Endod*. 1992;18:294–300.
- [9] Kartal N, Cimilli HK. The degrees and configurations of mesial canal curvatures of mandibular first molars. *J Endod*. 1997;23:358–362.
- [10] Gunday M, Sazak H, Garip Y. A comparative study of three different root canal curvature measurement techniques and measuring the canal access angle in curved canals. *J Endod*. 2005;31:796–798.
- [11] Nagy CD, Szabo J, Szabo J. A mathematically based classification of root canal curvatures on natural human teeth. *J Endod*. 1995;21:557–560.
- [12] Nagy CD, Keszthelyi G, Szabo J, et al. A computerized method for mathematical description of three-dimensional root canal axis. *J Endod*. 2000;26:639–643.
- [13] Schafer E, Diez C, Hoppe W, et al. Roentgenographic investigation of frequency and degree of canal curvatures in human permanent teeth. *J Endod*. 2002;28:211–216.
- [14] Peters OA, Laib A, Rueggsegger P, et al. Three-dimensional analysis of root canal geometry by high-resolution computed tomography. *J Dent Res*. 2000;79:1405–1409.
- [15] Bergmans L, Van Cleynenbreugel J, Wevers M, et al. A methodology for quantitative evaluation of root canal instrumentation using microcomputed tomography. *Int Endod J*. 2001;34:390–398.
- [16] Lee JK, Ha BH, Choi JH, et al. Quantitative three-dimensional analysis of root canal curvature in maxillary first molars using micro-computed tomography. *J Endod*. 2006;32:941–945.
- [17] Zhang R, Hu T. Root canal curvature, Letters to the Editor. *Int Endod J*. 2010;43:616–621.
- [18] Nikolaidis N, Pitas I. 3-D image processing algorithms. NJ, USA: John Wiley & Sons; 2000.
- [19] Zhang D, Chen J, Lan G, et al. The root canal morphology in mandibular first premolars: a comparative evaluation of cone-beam computed tomography and micro-computed tomography. *Clin Oral Invest*. 2017;21:1007–1012.
- [20] Szabo BT, Pataky L, Mikusi R, et al. Comparative evaluation of cone-beam CT equipment with micro-CT in the visualization of root canal system. *Ann Ist Super Sanita*. 2012;48:49–52.
- [21] Domark JD, Hatton JF, Benison RP, et al. An ex vivo comparison of digital radiography and cone-beam and micro computed

- tomography in the detection of the number of canals in the mesiobuccal roots of maxillary molars. *J Endod.* 2013;39:901–905.
- [22] Marca C, Dummer PM, Bryant S, et al. Three-rooted premolar analyzed by high-resolution and cone beam CT. *Clin Oral Investig.* 2013;17:1535–1540.
- [23] Ordinola-Zapata R, Bramante CM, Versiani MA, et al. Comparative accuracy of the Clearing Technique, CBCT and Micro-CT methods in studying the mesial root canal configuration of mandibular first molars. *Int Endod J.* 2017;50:90–96.
- [24] Michetti J, Maret D, Mallet JP, et al. Validation of cone beam computed tomography as a tool to explore root canal anatomy. *J Endod.* 2010;36:1187–1190.
- [25] Capar ID, Ertas H, Ok E, et al. Comparative study of different novel nickel-titanium rotary systems for root canal preparation in severely curved root canals. *J Endod.* 2014;40:852–856.
- [26] Yoo YS, Cho YB. A comparison of the shaping ability of reciprocating NiTi instruments in simulated curved canals. *Restor Dent Endod.* 2012;37:220–227.