JOURNAL OF ENDODONTICS
Printed in U.S.A.
VOL. 30, NO. 7, JULY 2004

Digital Radiograph Registration and Subtraction: A Useful Tool for the Evaluation of the Progress of Chronic Apical Periodontitis

Georgios Mikrogeorgis, DDS, PhD, Kleoniki Lyroudia, DDS, PhD, Ioannis Molyvdas, DDS, PhD, Nikolaos Nikolaidis, DDS, PhD, and Ioannis Pitas, DDS, PhD

The purpose of this study was to evaluate the suitability of a digital radiograph registration and subtraction software for a sensitive and reliable assessment of the progress of chronic apical periodontitis. Ninety cases of teeth with chronic apical periodontitis have been studied. In each case, a preoperative radiograph was taken, root canals were prepared, and a $Ca(OH)_2$ paste was placed in the root canals. Radiographic control and replacement of $Ca(OH)_2$ paste took place at 15-day intervals. The root canals were obturated 1.5 months after the first appointment. Recall radiographs were taken 0.5, 1.5, 3, 6, and 12 months after the obturation. All radiographs were taken for each case under constant conditions by using a direct digital radiography system. In each case, the preoperative, postoperative, and control and recall radiographs were digitally registered and pairwise subtracted. The resulting images were further processed by using contrast enhancement and pseudocoloring methods. Changes to the periapical tissue structure were easily detectable by using the above-mentioned methodology, even during short time intervals.

Comparative analysis of radiographic images of periapical lesions taken at monthly or yearly intervals provides an efficient tool for monitoring the progress of chronic apical periodontitis. Such radiographs can be acquired by conventional radiographic techniques or direct digital dental radiography. However, in both cases, numerous sources of technical and judgment errors exist (1, 2).

The first problem that complicates the conventional radiographic assessment is that the radiographs may differ in brightness, contrast, and acquisition geometry (2–4). Another factor that limits the efficiency of radiographic detection is the structured or anatomical "noise," which depends on the complexity of the anatomical background against which the changes of the periapical tissues often occur (5, 6). Reduction of structural noise can be achieved by digital subtraction radiography (DSR), which results in the elimination of identical image regions, i.e. regions that depict the same anatomical element in a series of radiographs obtained at different time intervals.

Furthermore, the evaluation of healing or expansion of a periapical lesion is usually qualitative and subjective. Publications that deal with the reliability of evaluation of periapical pathology from conventional periapical radiographs report large intraobserver (7–9) and even greater interobserver variance (8–12). Densitometric tracing of periapical radiographs (13) and observer radiographic scaling (14) have been used for quantitative and reliable assessment of the progress of chronic apical periodontitis. However, such techniques were unable to gain wide acceptance in clinical practice. DSR may provide improved accuracy, reliability, and sensitivity in diagnosing changes of periapical lesions (6, 15–22).

In general, DSR can be an important tool for the efficient monitoring of the progress of chronic apical periodontitis. To be effective, DSR should be preceded by an image-registration step and appropriate image normalization. The purpose of this study was to evaluate the suitability of a digital image-processing software, which was developed and combined all the above-mentioned operations, for a sensitive and reliable assessment of healing or expansion of chronic apical periodontitis after endodontic treatment, even during short time periods. For this reason, the progress of chronic apical periodontitis of 90 tooth cases was studied by using the software that was developed for this purpose.

MATERIALS AND METHODS

Ninety cases of teeth with periapical osseous lesions were used. In each case, a preoperative radiograph was taken, root canals were prepared according to the crown-down technique using the Profile, engine-driven, nickel-titanium files system, in combination with the hand stainless steel Hedstrom files (both from Dentsply-Maillefer, Maillefer Instruments SA, Ballaigues, Switzerland), and sodium hypochlorite (2.5%) as an irrigation solution. The working length was determined using an apex locator (Apex Finder Mod 7005 Analytic, Kerr International, West Collins, Orange). After root canal instrumentation, a $Ca(OH)_2$ paste was placed in the root canals. The $Ca(OH)_2$ paste was prepared by mixing powder of chemically pure $Ca(OH)_2$ (Merck & Co. Inc., NJ) with sodium

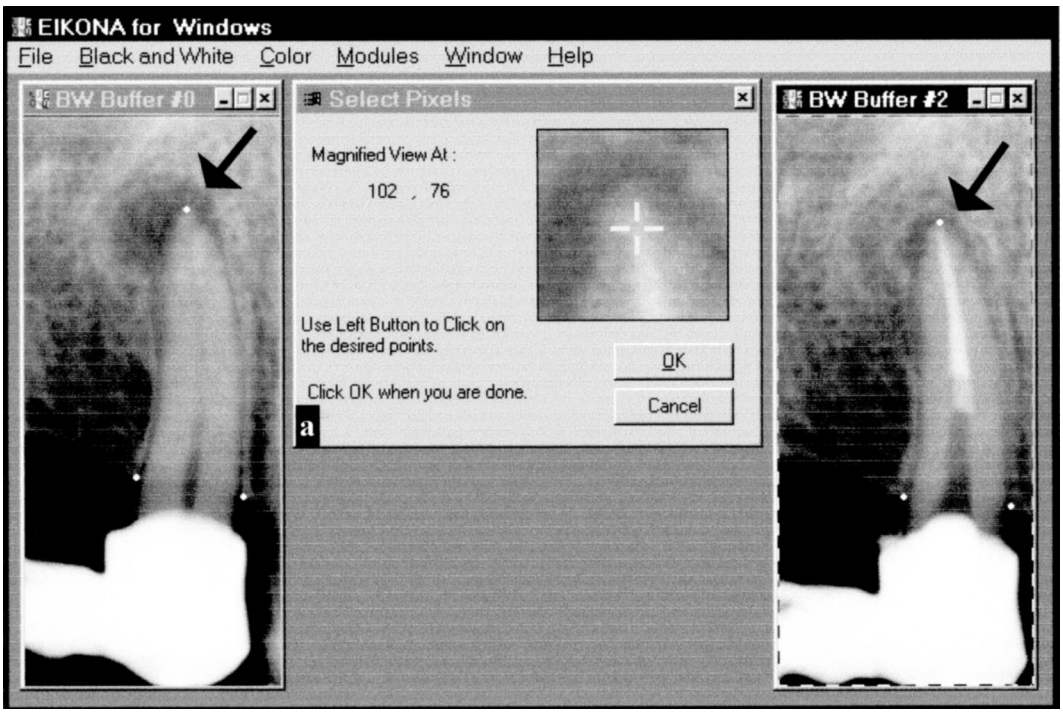

FIG 1. Landmark point selection on two digital periapical radiographic images. The selected landmark points on two digital radiographs are shown as white dots (pointed by arrows). (*a*) A magnification window helps the user to select accurately the corresponding landmark points between the two digital radiographs.

chlorite solution. Radiographic control and replacement of the $Ca(OH)_2$ paste in the root canals took place at 15-day intervals. The root canals were obturated 1.5 months after the first appointment by using the lateral condensation of gutta-percha points technique and Roth's 801 (Roth International Ltd., Chicago, IL) as a sealer. Recall radiographs were taken 0.5, 1.5, 3, 6, and 12 months after the final obturation of the root canals. All radiographs for each case were taken under constant conditions using the RadioVisioGraphy (RVG) direct digital intraoral radiography system (Trophy Radiology S.A., Paris, France) and an Oralix AC Densomat X-ray machine (Gendex Dental System, Milano, Italy, 65kV peak and 7.5mA mean). All radiographs were taken using the parallel technique. Appropriate intraoral sensor alignment instruments [Hawe Super-Bite (Hawe-Neos Dental, Bioggio, Switzerland)] were used for this purpose. In each case, the preoperative, postoperative, and control and recall radiographs were digitally subtracted from each other in pairs. In each pair, the later radiograph was subtracted from the earlier one. The resulting digital subtractive images were further processed using contrast enhancement and pseudocoloring methods to make the progress of the periapical lesions more easily distinguishable.

For registration, normalization, and subtraction procedures that were followed on the digital radiographs that were taken, a new digital image-processing software (23) was developed. The software runs on a Pentium PC under Windows 2000 operating system. To register the input digital radiographic images, taken in two different time instances by using the parallel technique, i.e. to correct the geometrical distortions (rotation, scaling, translation), before their subtraction, several pairs of user-defined landmark points are selected on them. The pairs of the selected landmark points must correspond to identical anatomical elements on the two digital radiographs. The selection of each landmark point is made by clicking with the mouse on the desired point of the corresponding digital radiographic image. The procedure of selecting landmark points on the two digital radiographic images is shown in Fig. 1. A magnification window helps the user to accurately select the desired landmark points on the two digital radiographs (Fig. 1a). The registration procedure is based both on those landmark points and on a refinement step that attempts to improve the initial results by using image-intensity information. Registration is accompanied by a normalization step that eliminates brightness and contrast differences between the two images. Finally, the two images are superimposed and subtracted.

To gain gold standards for the evaluation of the accuracy and the reliability of our digital registration, normalization, and subtraction software, 10 digital radiographs were randomly selected and subtracted from themselves. The resulting digital subtractive images were further processed by using contrast enhancement and pseudocoloring methods.

RESULTS

Healing of apical periodontitis was seen in all cases that were studied, both on clinical and radiographic examination. Two of our cases are shown in Figs. 2 and 3. The first mandibular molar that is shown in Fig. 3 was treated endodontically in combination with bisection of its roots.

Regions in which both radiographic images had the same intensity are shown as gray on the digital subtractive image. Regions in which the later radiograph is more radiolucent than the earlier one, i.e. regions that correspond to expansion of the periapical lesion, are demonstrated as dark regions on the digital subtractive image, whereas regions in which the later radiograph is more radio-opaque than the earlier one, i.e. regions that correspond to healing, are presented as white regions [Figs. 2 (j–r) and 3 (j–r)].



FIG 2. (*a*) Preoperative radiograph of a first mandibular molar (46). Intraoral fistula is traced with a gutta-percha cone. (*b, c*) Control radiographs after 0.5 and 1 month, respectively. (*d*) Postoperative radiograph 1.5 months later. (*e, f, g, h, i*) Recall radiographs 0.5, 1.5, 3, 6, and 12 months after obturation, respectively. (*j*) Result of digital subtraction of (*b*) from itself. (*j1*) Image (*j*) processed using contrast enhancement. (*k*) Result of digital subtraction of (*d*) from (*b*). (*k1*) Image (*k*) with contrast enhancement. (*k2*) Pseudocolored image (*k*). (*l*) Result of digital subtraction of (*c*) from (*a*). (*l1*) Image (*l*) processed using contrast enhancement. (*l2*) Image (*l*) processed using pseudocoloring. (*m*) Result of digital subtraction of (*f*) from (*a*). (*m1*) Image (*m*) with contrast enhancement. (*m2*) Pseudocolored image (*m*). (*n*) Result of digital subtraction of (*e*) from (*d*). (*n1*) Image (*n*) processed using contrast enhancement. (*n2*) Pseudocolored image (*n*). (*o*) Result of digital subtraction of (*f*) from (*d*). (*o1*) Image (*o*) with contrast enhancement. (*o2*) Image (*o*) processed using pseudocoloring. (*p*) Result of digital subtraction of (*g*) from (*d*). (*p1*) Image (*p*) processed using contrast enhancement. (*p2*) Pseudocolored image (*p*). (*q*) Result of digital subtraction of (*h*) from (*d*). (*q1*) Image (*q*) with contrast enhancement. (*q2*) Image (*q*) processed using pseudocoloring. (*r*) Result of digital subtraction of (*i*) from (*d*). (*r1*) Image (*r*) processed using contrast enhancement. (*r2*) Pseudocolored image (*r*).

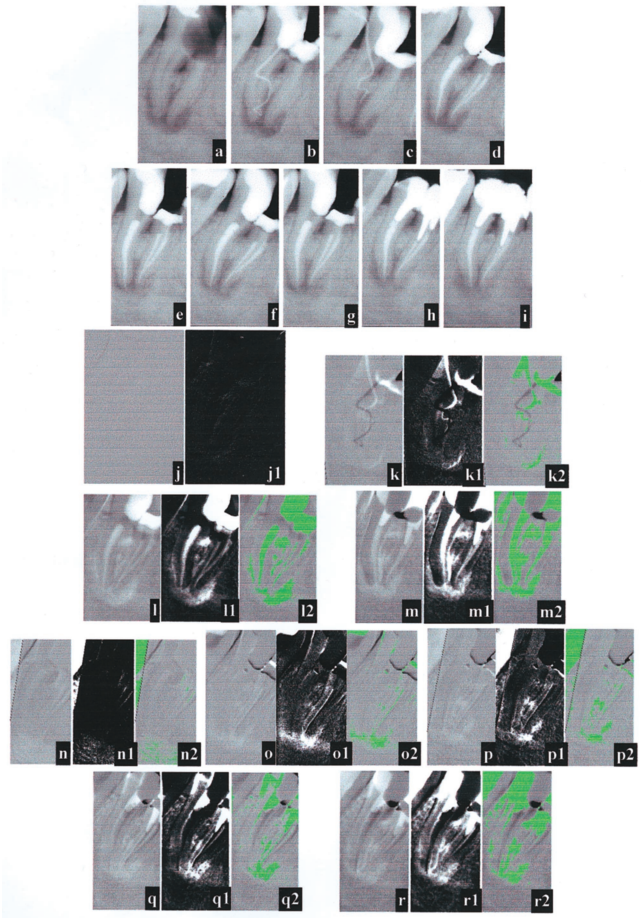

FIG 3. (*a*) Preoperative radiograph of another first mandibular molar (46) with an intraoral sinus tract. (*b, c*) Control radiographs after 0.5 and 1 month, respectively. (*d*) Postoperative radiograph 1.5 months later. (*e, f, g, h, i*) Recall radiographs 0.5, 1.5, 3, 6, and 12 months after the obturation, respectively. (*j*) Result of digital subtraction of (*a*) from itself. (*j1*) Image (*j*) processed using contrast enhancement. (*k*) Result of digital subtraction of (*c*) from (*b*). (*k1*) Image (*k*) with contrast enhancement. (*k2*) Pseudocolored image (*k*). (*l*) Result of digital subtraction of (*f*) from (*a*). (*l1*) Image (*l*) processed using contrast enhancement. (*l2*) Pseudocolored image (*l*). (*m*) Result of digital subtraction of (*i*) from (*a*). (*m1*) Image (*m*) with contrast enhancement. (*m2*) Image (*m*) processed using pseudocoloring. (*n*) Result of digital subtraction of (*e*) from (*d*). (*n1*) Image (*n*) processed using contrast enhancement. (*n2*) Pseudocolored image (*n*). (*o*) Result of digital subtraction of (*f*) from (*d*). (*o1*) Image (*o*) with contrast enhancement. (*o2*) Image (*o*) processed using pseudocoloring. (*p*) Result of digital subtraction of (*g*) from (*d*). (*p1*) Image (*p*) processed using contrast enhancement. (*p2*) Pseudocolored image (*p*). (*q*) Result of digital subtraction of (*h*) from (*d*). (*q1*) Image (*q*) with contrast enhancement. (*q2*) Image (*q*) processed using pseudocoloring. (*r*) Result of digital subtraction of (*i*) from (*d*). (*r1*) Image (*r*) processed using contrast enhancement. (*r2*) Pseudocolored image (*r*).

By applying contrast-enhancement methods on the digital subtractive images, the white areas that demonstrate healing of the periapical lesions were made more distinguishable over an homogeneous dark background [Figs. 2 (j1–r1) and 3 (j1–r1)]. By using pseudocoloring methods, the white areas of the digital subtractive images that demonstrate healing of the periapical lesions were colored green [Figs. 2 (j2–r2) and 3 (j2–r2)].

The results showed that the digital radiograph registration, normalization, and subtraction software that was developed and used in this work could detect with sufficient accuracy and reliability even the most subtle structural changes in periapical tissues that occurred in a few days interval [Figs. 2 (n, n1, n2) and 3 (k, k1, k2, n, n1, n2)]. For the 1.5-month interval, the reliability and accuracy of the detection of the healing procedures in the periapical region using this methodology increased significantly [Figs. 2 (o, o1, o2) and 3 (o, o1, o2)]. In the 1-yr recall, lesions in most cases were totally healed, which was obvious using this method, a fact that

verified the reliability of their early detection [Figs. 2 (r, r1, r2) and 3 (r, r1, r2)].

The subtractive images that were used as gold standards showed that our software is capable of performing accurate digital radiographic image registration, normalization, and subtraction. Also, the images that were used as gold standards demonstrated that even if a radiograph was digitally subtracted from itself, a subtle image of the anatomical background remains at the subtractive image [Figs. 2 (j, j1) and 3 (j, j1)].

DISCUSSION

Kullendorff et al. (16, 19) found that DSR could significantly increase the detectability of periapical bone lesions, particularly of those confined to cancellous bone. In two similar studies (18, 21), it was concluded that DSR might provide improved accuracy and sensitivity in detecting changes of both cortical and cancellous periapical bone. Also, the importance of DSR as a tool for the evaluation of the healing process of periapical lesions has been demonstrated in the follow-up studies of endodontically treated teeth (17, 20, 22). All these findings are in accordance with our results, i.e. that the DSR method is a good tool used for a reliable and sensitive diagnosis even of subtle changes in the structure of periapical tissues during short time intervals.

The successful use of DSR depends directly on the radiographic image reproducibility. Reproducibility is associated with radiographic contrast, brightness, and geometrical distortions. It has been shown that radiographic contrast and brightness distortions can be corrected if they remain within certain limits (4, 24). The digital image-processing procedures implemented in the developed software seem to be able to correct effectively the radiographic contrast and brightness distortions.

The main problem associated with DSR is the radiographic geometrical distortion, which depends on the reproducibility of the relative position and orientation of the X-ray beam, the tooth, and the receptor (6, 17, 24, 25). Two types of angulation distortions have been reported (3). Reversible geometrical distortions are caused by misalignment of the image receptor with respect to the tooth. These distortions can be reduced by using digital image-processing methods. Irreversible geometrical distortions are caused by misalignment of the X-ray source with respect to the tooth. Such distortions cannot be corrected because of the large variation of X-ray source positions with respect to the tooth (17, 24).

Therefore, the application of the parallel technique for radiographic acquisition by using an appropriate intraoral receptor-alignment tool is obligatory and provides a high degree of reproducibility. The proper use of cephalometric head stabilization methods (26), as well as the commercially available alignment instruments, customized by occlusal stent (27) or impression material (25, 28) on the bite block, were proposed for alignment standardization. Rudolph and White (25) proposed the combination of Regisil, an elastic impression material, and a Rinn XCP bite block as the most reproducible acquisition procedure. Unfortunately, all these methods are too cumbersome to be used in routine clinical practice or require extensive fabrication and exhibit limited precision (24, 25, 29, 30). Therefore, in this clinical study, which involved a large number of cases with long recall times, it was decided not to use any of these methods. Furthermore, the registration algorithm that was developed to be used in our clinical cases has been proved to compensate effectively the planar rigid transforms (i.e. translations and rotations) and the vertical angulation changes of the two radiographs that were used for subtraction.

Moreover, many researchers have reported that the angulation errors on the two radiographs to be subtracted are unavoidable. The same researchers have defined the acceptable range of these errors to come up with diagnostically useful information when DSR is used to be 0.7 (30), 1, (31, 32), or even 3 degrees (31, 33, 34).

The subtractive images that were used as gold standards have proven that our digital image-processing method is capable of accurate normalization and alignment of the two radiographs to be subtracted. However, even in these images, a subtle radiographic image of the anatomical background could be observed, demonstrating that it is impossible to achieve perfect normalization and superimposition of two radiographs. This observation is in accordance with the findings of Grondahl et al. (6) and Grondahl (35), which have reported that this anatomical "noise" on the subtractive images is acceptable and even useful for the anatomical localization of the lesions. CONCLUSIONS

The progress of chronic apical periodontitis can be evaluated with reliability and sensitivity by using our digital image registration, normalization, and subtraction method. This is a promising tool for the future of clinical practice.

Supported by the Greek Ministry of Research and Technology, Research Grant PENED'99, No 1926.

Dr. Lyroudia is associate professor, and Dr. Molyvdas is assistant professor, and Dr. Mikrogeorgis is affiliated with the Department of Endodontology, Dental School; Dr. Nikolaidis is lecturer, and Dr. Pitas is professor, Department of Informatics, Aristotle University of Thessaloniki, Thessaloniki, Greece.

Address requests for reprints to Dr. Georgios Mikrogeorgis, 11, Pindarou Str., 546 39 Thessaloniki, Greece. E-mail: gmicro@dent.auth.gr.

References

1. Reit C. On decision making in endodontics. A study of diagnosis and management of periapical lesions in endodontically treated teeth. Swed Dent J Suppl 1986;41:1–30.
2. Huumonen S, Orstavik D. Radiological aspects of apical periodontitis. Endod Topics 2002;1:3–25.
3. Webber RL, Ruttimann UE, Groenhuis RAJ. Computer correction of projective distortions in dental radiographs. J Dent Res 1984;63:1032–6.
4. Ruttimann UE, Webber RL, Schmidt E. A robust digital method for film contrast correction in subtraction radiography. J Periodontal Res 1986;21: 486–95.
5. Revesz G, Kundel HL, Graber MA. The influence of structured noise on the detection of radiologic abnormalities. Invest Radiol 1974;9:479–86.
6. Grondahl HG, Grondahl K, Webber RL. A digital subtraction technique for dental radiography. Oral Surg Oral Med Oral Pathol 1983;55:96–102.
7. Brynolf I. Roentgenologic periapical diagnosis. I. Reproducibility of interpretation. Sven Tandlak Tidskr 1970;63:339–44.
8. Goldman M, Pearson AH, Darzenta N. Reliability of radiographic interpretations. Oral Surg Oral Med Oral Pathol 1974;38:287–93.
9. Abdel Wahab MH, Greenfield TA, Swallow JN. Interpretation of intraoral periapical radiographs. J Dent 1984;12:302–13.
10. Reit C, Hollender L. Radiographic evaluation of endodontic therapy and the influence of observer variation. Scand J Dent Res 1983;91:205–12.
11. Halse A, Molven O. A strategy for the diagnosis of periapical pathosis. J Endodon 1986;12:534–8.
12. Kaffe I, Gratt BM. Variations in the radiographic interpretation of the periapical dental region. J Endodon 1988;14:330–5.
13. Duinkerke AS, van de Poel AC, Doesburg WH, Lemmens WA. Densitometric analysis of experimentally produced periapical radiolucencies. Oral Surg Oral Med Oral Pathol 1977;43:782–97.
14. Orstavik D, Kerekes K, Eriksen HM. The periapical index: a scoring system for radiographic assessment of apical periodontitis. Endod Dent Traumatol 1986;2:20–34.
15. Pascon EA, Introcaso JH, Langeland K. Development of predictable periapical lesion monitored by subtraction radiography. Endod Dent Traumatol 1987;3:192–208.
16. Kullendorff B, Grondahl K, Rohlin M, Henrikson CO. Subtraction radiography for the diagnosis of periapical bone lesions. Endod Dent Traumatol 1988;4:253–9.

17. Orstavik D, Farrants G, Wahl T, Kerekes K. Image analysis of endodontic radiographs: digital subtraction and quantitative densitometry. Endod Dent Traumatol 1990;6:6–11.

18. Tyndall DA, Kapa SF, Bagnell CP. Digital subtraction radiography for detecting cortical and cancellous bone changes in the periapical region. J Endodon 1990;16:173–8.

19. Kullendorff B, Grondahl K, Rohlin M, Nilsson M. Subtraction radiography of interradicular bone lesions. Acta Odontol Scand 1992;50:259–67.

20. Delano EO, Tyndall D, Ludlow JB, Trope M, Lost C. Quantitative radiographic follow-up of apical surgery: a radiometric and histologic correlation. J Endodon 1998;24:420–6.

21. Dove SB, McDavid WD, Hamilton KE. Analysis of sensitivity and specificity of a new digital subtraction system: an in vitro study. Oral Surg Oral Med Oral Pathol Oral Radiol Endod 2000;89:771–6.

22. Yoshioka T, Kobayashi C, Suda H, Sasaki T. An observation of the healing process of periapical lesions by digital subtraction radiography. J Endodon 2002;28:589–91.

23. EIKONA REGISTRATION, Alphatec. Available at: http://www.alphatecltd.com. Accessed 2002.

24. Lehmann TM, Grondahl HG, Benn DK. Computer-based registration for digital subtraction in dental radiology. Dentomaxillofac Radiol 2000;29:323–46.

25. Rudolph DJ, White SC. Film-holding instruments for intraoral subtraction radiography. Oral Surg Oral Med Oral Pathol 1988;65:767–72.

26. Jeffcoat MK, Reddy MS, Webber RL, Williams RC, Ruttimann UE. Extraoral control of geometry for digital subtraction radiography. J Periodontal Res 1987;22:396–402.

27. McHenry K, Hausmann E, Wikesjo U, et al. Methodological aspects and quantitative adjuncts to computerized subtraction radiography. J Periodontal Res 1987;22:125–32.

28. Duckworth JE, Judy PF, Goodson JM, Socransky SS. A method for the geometric and densitometric standardization of intraoral radiographs. J Periodontol 1983;54:435–40.

29. Shrout MK, Hildebolt CF, Vannier MW. Alignment errors in bitewing radiographs using uncoupled positioning devices. Dentomaxillofac Radiol 1993;22:33–7.

30. Janssen PT, van Palenstein Helderman WH, van Aken J. The effect of in-vivo-occurring errors in the reproducibility of radiographs on the use of the subtraction technique. J Clin Periodontol 1989;16:53–8.

31. Rudolph DJ, White SC, Mankovich NJ. Influence of geometric distortion and exposure parameters on sensitivity of digital subtraction radiography. Oral Surg Oral Med Oral Pathol 1987;64:631–7.

32. Davis M, Allen KM, Hausmann E. Effects of small angle discrepancies on interpretations of subtraction images. Oral Surg Oral Med Oral Pathol 1994;78:397–400.

33. Ruttimann UE, Okano T, Grondahl HG, Grondahl K, Webber RL. Exposure geometry and film contrast differences as bases for incomplete cancellation of irrelevant structures in dental subtraction radiography. Proc SPIE Digital Radiography 1981;314:372–77.

34. Grondahl K, Grondahl HG, Webber RL. Influence of variations in projection geometry on the detectability of periodontal bone lesions. A comparison between subtraction radiography and conventional radiographic technique. J Clin Periodontol 1984;11:411–20.

35. Grondahl K. Computer-assisted subtraction radiography in periodontal diagnosis. Swed Dent J Suppl 1987;50:1–44.